



## PSEUDO SIGN OF LESER TRELAT?

Gabriella Jesslyn Evania<sup>1</sup>, Henry<sup>1</sup>, Irene Dorthy Santoso<sup>2,4</sup>, Sony Sugiharto<sup>3,4</sup>

<sup>1</sup> Medical Doctor Professional Study Program, Faculty of Medicine, Universitas Tarumanagara, Jakarta, Indonesia

<sup>2</sup> Department of Dermato-Venereology, Faculty of Medicine, Universitas Tarumanagara, Jakarta, Indonesia

<sup>3</sup> Department of Pathology Anatomy, Faculty of Medicine, Universitas Tarumanagara, Jakarta Indonesia

<sup>4</sup> Sumber Waras Hospital, Jakarta, Indonesia

**Corresponding Author:** Gabriella Jesslyn Evania, Medical Doctor Professional Study Program, Faculty of Medicine, Universitas Tarumanagara.

E-Mail: [gabriellajesslyn9@gmail.com](mailto:gabriellajesslyn9@gmail.com)

**Received** 13 September, 2021; **Accepted** 24 September, 2021; **Online Published** 28 Januari, 2022

### Abstract

Leser Trelat sign is a rare condition. Mostly, the sign appears with underlying malignant disease. A 74-year-old man presented to the hospital with multiple lesions distributed over multiple parts of the body that are increasing in number within a year. No history of malignancy within the family. Based on the anamnesis and characteristic appearance of the skin lesions, the diagnosis is still vague, therefore, we need to perform a histopathology examination. Following the skin biopsy, we perform electrocauterization to remove the other lesions. The histopathology examination results indicate that the patient's diagnosis is not a malignancy, rather he was diagnosed with seborrheic keratosis.

**Keywords:** *Leser Trelat Sign; Seborrheic Keratosis; Malignancy; Paraneoplastic Cutaneous*

## INTRODUCTION

The Leser-Trelat sign is a rare condition defined as sudden eruption of multiple Seborrheic Keratosis (SK) with rapid increase in size caused by malignancy.<sup>1,2</sup> Leser-Trelat sign are common in elderly, number of cases have been reported the average age of onset approximately 61 years of age.<sup>3</sup> Predilection amongst sex or any race had not been reported.<sup>3</sup>

Mostly, Leser-Trelat sign appear with underlying malignant disease.<sup>1,2</sup> This sign considered to be a rare paraneoplastic syndrome which believed to be an internal malignancy.<sup>3,4</sup> Usually, the paraneoplastic syndrome in Leser-Trelat sign associated with adenocarcinoma of gastrointestinal tract (gastric, colon, and rectal).<sup>3,5</sup> The most common primary tumor site is in gastric.<sup>5</sup> In older patients, SK can also be found without underlying of malignant disease, the

appearance of SK without any underlying disease has been defined as a pseudo sign of Leser-Trelat.<sup>6</sup>

Histopathological examination of a biopsied lesion of SK to confirm any sign of malignancy. The histopathological examination may be required to distinguish from other melanocytic neoplasm that lacking typical exam findings.<sup>3</sup> Symptomatic lesion of SK may be removed with cryotherapy, curettage, shave removal, and electrodesiccation, asymptomatic lesion does not require any further treatment other than treatment of the malignancy.<sup>3</sup> Most of dermatoses paraneoplastic syndrome will be disappeared when the primary tumor is removed and will be reappear when the primary tumor recurrent or metastases of the cancer.<sup>7</sup> In this case report, we present a case of multiple eruption of SK without internal malignancy confirmed.

## CASE REPORT

A seventy-four-year-old asian man was admitted to dermatovenereology clinic at a hospital in Jakarta with multiple lesions distributed over his back, chest and stomach that are increasing in number within a year and reoccurred after electrocauter he had a year ago. Lesions that were initially asymptomatic, became itchy. There is no history of malignancy on patient and his family.

At dermatological examination on back region showed multiple well circumscribed verrucous plaque and papules, in brown to black color. Size was varied from 1 mm to 30 mm.

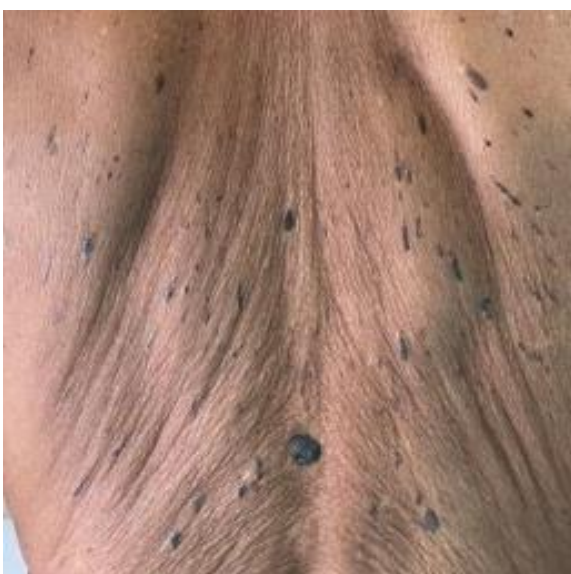
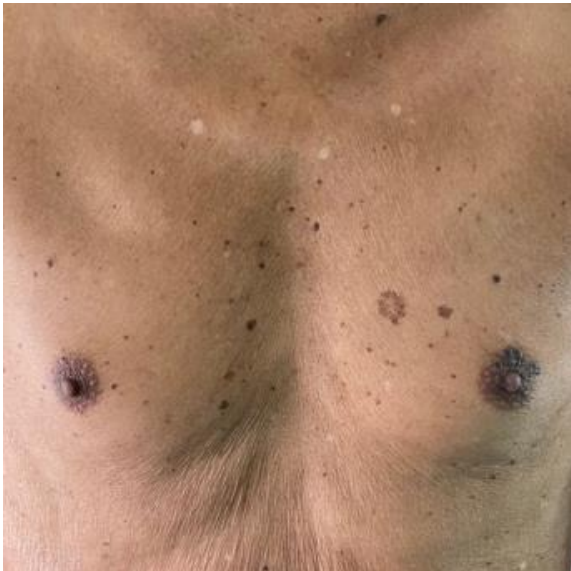
Figure 1, 2. Multiple seborrheic keratosis distributed

on the chest and back region

We performed excisional biopsy on the most prominent lesion at the back after aseptic procedure and local anesthesia. After we took the lesion, we sutured him back and gave him the post procedure treatment. The procedure was performed for identification purpose. Histopathological examination of the lesion showed as hyperplasia of epidermal with flat base. The lesion also showed hyperkeratosis with acanthotic epidermis and keratin cyst. The brown pigment showed within the cells. No sign of malignancy found.

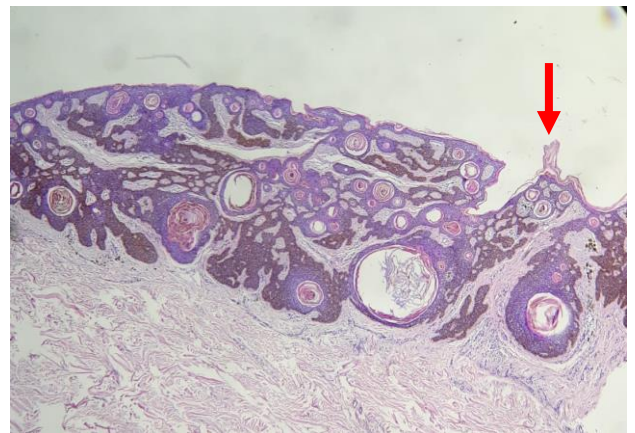


Figure 3. Hyperkeratosis. HE, 4x10:40.

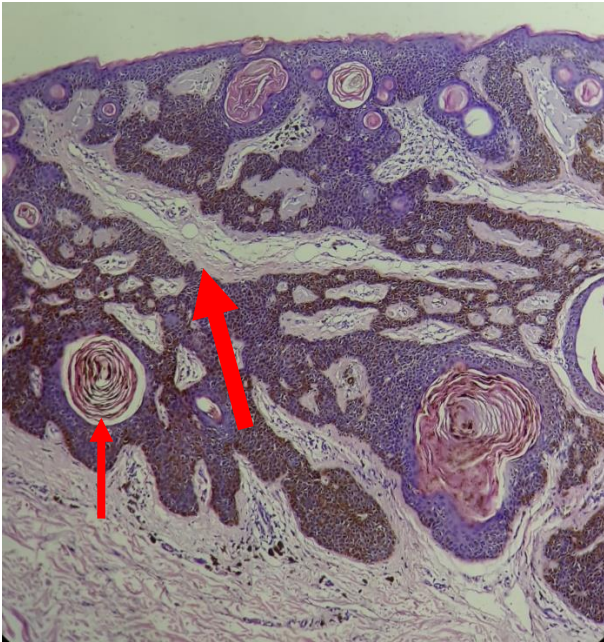

Figure 4. Keratin cyst. HE10x10.

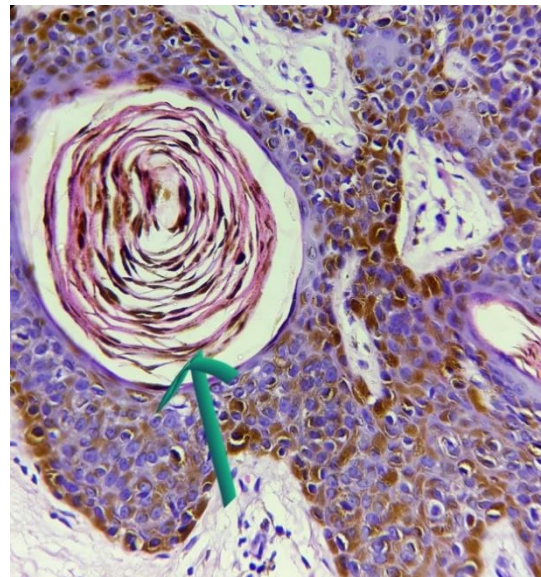


Figure 5. Keratin cyst. HE 40x10.

Mupirocin ointment was given to patient as a post procedure treatment. As the result was out, we revealed to the patient there was no malignancy found and offered him electrocauterization as the next procedure that he could receive to remove the remaining lesions and also due to the hospital's availability. We suggested the patient to avoid the risk factors such as too much exposure of sunlight.

## DISCUSSION

Sudden eruption of SK with rapid increase in size may caused by malignancy is defined as Leser-Trelat sign. Leser-Trelat sign are commonly happen in elderly, usually occur 61 years of age.<sup>1,2</sup> The appearance of rapid eruptive lesions in individuals age of 30s are not common.<sup>3</sup> The etiopathogenesis is not completely understood, but there is strong suspicion that the neoplasm releases cytokines and growth factors that stimulating the SK eruption.<sup>3</sup> Another factor that are related to the eruption is chronic ultraviolet (UV) exposure. Chronic UV exposure has a higher chance of Amyloid Precursor Protein (APP) expression,

overexpression of APP may promote eruption of SK and UV damage of the skin.<sup>9</sup>

These lesions may present as papules, macule, and plaques.<sup>3</sup> The lesions tend to have a well-circumscribed and darker color from skin tone, they may appear tan, brown or some may be black. As seen on physical examination, lesion usually in a symmetrical pattern and resemble a "christmas tree", "splash", or "raindrop".<sup>3</sup> The most common location is in the back, followed by extremities, face, neck, and abdomen. In our case, the lesion predominantly distributed on the back and chest shown as brown plaques and resembled as a "christmas tree", the lesions which occurred now has the same pattern as seen a year ago.

Some of cases often look for treatment because of the pruritus.<sup>3</sup> Sudden and rapid eruption of SK accompanied with pruritus seems to be a key criterion for suspicion of malignancy, in this case, pruritus is one of the reasons that made the patient looks for the treatment.<sup>10</sup>

Leser-Trelat sign is a rare sign that mostly appear with an underlying internal malignancy. Most frequent carcinomas are adenocarcinoma of

gastrointestinal tract.<sup>3,5</sup> In some of cases that have been reported, recurrence of Leser-Trelat sign may be a sign of metastases of the cancer.<sup>8</sup> Leser-Trelat sign may not be a sign of malignancy in some conditions such as acanthosis nigricans, infection of Human Immunodeficiency Virus (HIV), and psoriasis.<sup>10</sup> There are number of studies show that pseudo sign of Leser-Trelat may appeared during chemotherapy. Most cases reported, the appearance of lesions is following docetaxel treatment and cytarabine.<sup>11,12,13</sup>

Leser-Trelat sign may occur before, after and at the time of malignancy diagnosis.<sup>14</sup> Recent study from Husein et al shows eruptions of SK happen before the diagnosis of malignancy made.<sup>15</sup>

In this case, the SK lesions reoccurred within a year, even after the electrocauter he had a year ago, but based on the information from the patient, there is no history of malignancy neither on him or his family and also there is no other sign and symptoms of any internal malignancy.

We report this case of recurrence of the lesions as we suspected as Leser-Trelat sign to highlight that recurrence and symptomatic of SK lesion that need a further treatment may not be a sign of malignancy. A detailed history and physical examination are needed with a confirmation of histopathological examination to distinguish from other melanocytic neoplasm. There have been no standardized tools or criteria to define Leser-Trelat sign.<sup>3</sup> In this case, we can't determine whether it's Leser-Trelat sign or it's just a pseudo sign of Leser-Trelat, due to patient's absence to receive any further examination to rule out any malignancy after the result was out.

## CONCLUSION

The relationship between Leser-Trelat sign and malignancy remains unclear in this case regarding any limitation information in rule out underlying malignant disease in the patient. The best suggestion that we can

offer is the patient needs to avoid risk factors such as too much exposure of sunlight.

## REFERENCES

1. Schwartz R. Sign of leser-trelat. *J Am Acad Dermatol* [Internet]. 1996 Jul [Cited 2020 Nov 30];35(1):88-95. Available from: <https://pubmed.ncbi.nlm.nih.gov/8682971/>.
2. Asri H, Soualhi M. The sign of leser-trelat: think in the adenocarcinoma of the lug. *Pan African Medical Journal* [Internet]. 2018 Aug 10 [Cited 2020 Nov 30];30:270. Available from: <https://www.ncbi.nlm.nih.gov/pmc/articles/PMC6317404/#:~:text=The%20Leser%2DTrelat%20sign%20is,stomach%2C%20exceptionally%20of%20the%20lung.>
3. Bernett CN, Schmieder GJ. *Leser trelat sign* [Internet]. Florida: StatPearls Publishing; 2019 Mar 21 [updated 2020 Sep ; cited 2020 Nov 30]. Available from: <https://www.ncbi.nlm.nih.gov/books/NBK470554/>.
4. Gori N, Esposito I, Regno LD, D'amore A, Peris K, Stefani AD, et al. Leser-trelat sign as a rare manifestation of cutaneous melanoma. *Dermatol Reports* [Internet]. 2020 Jul 6 [cited 2020 Nov 30];12(1):8665. Available from: <https://www.ncbi.nlm.nih.gov/pmc/articles/PMC7366130/>.
5. Wagner RF, Wagner KD. Malignant neoplasms and the leser-trélat sign. *Archives of Dermatology* [Internet]. Sep 1981 [cited 2020 Nov 30]; 117(9):598-99. Available from: <https://jamanetwork.com/journals/jamadermatology/article-abstract/542485>.
6. Chakradeo K, Narsinghpura K, Ekladios A.

- Sign of Leser-trelat. *BMJ Case Reports* [Internet]. 2016 Apr 8 [cited 2020 Nov 30];2016. Available from: <https://casereports.bmj.com/content/2016/bcr-2016-215316>.
7. Ponti G, Luppi G, Losi L, Giannetti A, Seidenari S. Leser-trelat syndrome in patients affected by six multiple metachronous primitive cancers. *Journal of Hematology and Oncology* [Internet]. 2010 Jan 11 [cited 2020 Nov 30];3:2. Available from: <https://www.ncbi.nlm.nih.gov/pmc/articles/PMC2820021/#:~:text=Leser-Tr%C3%A9lat%20syndrome%20is%20characterized,kidney%2C%20liver%2C%20and%20pancreas>
  8. Stollmeier A, Rosario BA, Mayer BL, Frandoloso GA, Magalhaes FL, Marques GL. Seborrheic keratoses as the first sign of bladder carcinoma: case report of Leser-trélat sign in a rare association with urinary tract cancer. *Case Reports in Medicine* [Internet]. 2016 Nov [cited 2020 Nov];2016. Available from: <https://doi.org/10.1155/2016/4259190>
  9. Wollina U. Recent advances in managing and understanding seborrheic keratosis [Internet]. *F1000Research*. 2019 Aug 28 [cited 2020 Dec 1];2019:8. Available from: <https://www.ncbi.nlm.nih.gov/pmc/articles/PMC6719672/>
  10. Li M, Yang LJ, Zhu XH, Zhang YS, Sun H, Jiang PD, Zhang RR, Tang W, Cai Y, et al. The Leser-Trélat sign is associated with nasopharyngeal carcinoma: case report and review of cases reported in China. *Clinical and Experimental Dermatology: Clinical dermatology* [Internet]. 2009 Jan [cited 2020 Dec 1];34(1):52-4. Available from: <https://pubmed.ncbi.nlm.nih.gov/19076792/>
  11. Patton T, Zirwas M, Nieland-Fisher N, Jukic D. Inflammation of seborrheic keratoses caused by cytarabine: a pseudo sign of Leser-Trelat. *Journal of drugs in dermatology: JDD* [Internet]. 2004 Sep 1 [Cited 2020 Dec 2];3(5):565-6. Available from: <https://europepmc.org/article/med/15552612>
  12. Kowalzick L, Truhm B, Eickenscheidt L. Sign and pseudo-sign of Leser-trelat. *J Drugs Dermatol* [Internet]. 2014 Jan [Cited 2020 Dec 2];13(1):14. Available from: <https://jddonline.com/articles/dermatology/S1545961614P0014X>
  13. Lilly E, Granter SR, Haynes HA, Ibrahim OA. Chemotherapy-induced inflammatory seborrheic keratoses in a man with acute myeloid leukemia: a variant of Leser-Trélat sign?. *Cutis* [Internet]. 2012 Nov 1 [Cited 2020 Dec 2];90(5):235-6. Available from: <https://europepmc.org/article/med/23270192>
  14. Westrom DR, Berger TG. The sign of Leser-Trélat in a young man. *Archives of dermatology* [Internet]. 1986 Dec 1 [Cited 2020 Dec 2];122(12):1356-7. Available from: <https://jamanetwork.com/journals/jamadermatology/article-abstract/547746>
  15. Husain Z, Ho JK, Hantash BM. Sign and pseudo-sign of Leser-Trélat: case report and a review of the literature. *J Drugs Dermatol* [Internet] 2013 [Cited 2020 Dec 2];12; e79-87. Available from: <https://europepmc.org/article/med/23652964>